

Soft tissue molding technique in cleft lip and palate patient using laser surgery in combination with orthodontic appliance: A case report

Pornpat Theerasopon ¹, Tasanee Wangsrimongkol ² and Sajee Sattayut ³

1: Department of Orthodontics, School of Dentistry, University of Phayao, Phayao, Thailand and Lasers in Dentistry Research Group, Khon Kaen University

2: Department of Orthodontics, Faculty of Dentistry, Khon Kaen University

3: Department of Oral and Maxillofacial Surgery, Faculty of Dentistry, Khon Kaen University, Khon Kaen, Thailand and Lasers in Dentistry Research Group, Khon Kaen University

Background: Although surgical treatment protocols for cleft lip and palate patients have been established, many patients still have some soft tissue defects after complete healing from surgical interventions. These are excess soft tissue, high attached fraena and firmed tethering scars. These soft tissue defects resulted shallowing of vestibule, restricted tooth movement, compromised periodontal health and trended to limit the maxillary growth. The aim of this case report was to present a method of correcting soft tissue defects after conventional surgery in cleft lip and palate patient by using combined laser surgery and orthodontic appliance.

Case report: A bilateral cleft lip and palate patient with a clinical problem of shallow upper anterior vestibule after alveolar bone graft received a vestibular extension by using CO₂ laser with ablation and vaporization techniques at 4 W and continuous wave. A customized orthodontic appliance, called a buccal shield, was placed immediately after surgery and retained for 1 month to 3 months until complete soft tissue healing. The procedures were performed 2 episodes. Both interventions used the same CO₂ laser procedure. The first treatment resulted in partial re-attachment of soft tissue at surgical area. The second laser operation with the proper design of buccal shield providing passive contact with more extended flange resulting in a favorable outcome from 1 year follow up. Then the corrective orthodontic treatment could be continued effectively.

Conclusion: The CO₂ laser surgery was a proper treatment for correcting soft tissue defects and the design of buccal shield was a key for success in molding surgical soft tissue.

Key words: photoablation · cleft · orthodontic treatment · soft tissue molding · vestibular stent

Introduction

Clefts of the lip and/or palate (CLP) was one of the most common craniofacial birth defects and had the incident rate up to 2.49 per 1,000 of new born babies in Thailand of which the highest incidence in the world ¹). Still CLP has been one of the major public health problems in Thailand and globally. This also

affected quality of life of patients and their parents due to a long term medical treatment over 15 years. Owing to the multi-deformity defects related to structural and functional development of oral and maxillofacial organs, these required a series of treatment beginning at birth until adolescence period or longer depended on the severity of deformity by a multidisciplinary team approach. The major purpose of treatment was to correct deformities and create a normal function. Current concept of treatment for normal occlusion required both orthodontic treatment and several surgical interventions such as cheiloplasty, palatoplasty, alveolar bone grafting, orthognathic surgery, distraction osteo-

Addressee for Correspondence:

Assoc. Prof Sajee Sattayut, DDS PhD
Lasers in Dentistry Research Group, Khon Kaen University
and Oral Surgery Department, Faculty of Dentistry Khon
Kaen University, 123 Faculty of Dentistry, Khon Kaen,
Thailand, 40002
Tel: +66 93 546 6178
E-mail: sajee@kku.ac.th

Received date: August 16th, 2016

Accepted date: October 18th, 2016

genesis and other surgery for correcting defects, if needed ²⁾.

One of the crucial interventions was alveolar bone grafting used an autogenic iliac crestal bone for cleft site reconstruction. In order to gain full soft tissue coverage for ensuring success of bone grafting into the cleft site, the designs of local flap for this purpose inevitably resulting tension of the surrounding soft tissue. The post-operative excessing of soft tissue at the cleft site, tethering scar at the alveolar ridge of incisors and shallowing of vestibule were usually found ²⁾. Even in complete healing, the soft tissue encroaching gingivae surrounding teeth was still remarked. All of these post-operative soft tissue characters clinically appeared to restrict tooth movement, compromise periodontal health and trend to limit the maxillary growth.

Regarding the correction of soft tissue defects from post-operative procedure, this required a combination of surgical treatment and orthodontic appliance to reshape defected areas. However, conventional surgery with scalpel had some limitations due to scar formation and high rate of relapse at defected area from secondary intention healing. Consequently, there were several post-operative complications such as bleeding, high level of inflammation which result in delayed healing process and large exposed wound area leading to surgical trauma pain ³⁾. These resulted no possibility for patients to wear orthodontic appliance for preserving corrected soft tissue.

Laser surgery was an alternative treatment for correcting defects adjuvant to conventional surgical technique due to ease of use and reduced postoperative complication ⁴⁾. The advantages of using laser surgery as an complimentary technique to conventional method were surgery with hemostasis, providing clear filed of operation, less operative time, less postsurgical pain and discomfort, no suture required, sterilization of wound during operation and reduced risk of postoperative infection ^{3, 5)}. Moreover laser surgery had minimal wound contraction allowing the better outcome of treatment for wearing prosthesis after laser surgery ⁶⁾. There were many types of laser efficiently used for soft tissue surgery such as 1064 nm neodymium yttrium aluminium garnet (Nd: YAG) laser, 800 to 900 nm diode laser, 10600 nm carbon dioxide (CO₂) laser and 2940 nm Erbium YAG (Er: YAG) laser.

Among all types of lasers for oral soft tissue surgery, the CO₂ laser was a high absorbed by specimen containing large amount of water and organic matter such as soft tissue. Moreover, CO₂ laser could coagulate small blood vessels providing sufficient coagulation without extensive lateral heat effect.

Subsequently, surgical pain usually persisted for only few seconds after finish of ablating ⁷⁾ which gains more compliant of patients. Supporting from the in vivo study of Fisher and Frame ⁸⁾ which created CO₂ laser wounds on buccal mucosa, floor of mouth, tooth and alveolar mucosa of dogs. The visual inspection revealed that there was no undue pain among all subjects and all could continue their diet without difficulty. From the histological investigation from the study of Fisher et al ⁹⁾ which compared the healing from CO₂ laser and conventional excision of dog's buccal mucosa, there were minimal damage to adjacent tissues which led to less inflammation of surrounding tissues and fewer myofibroblasts resulting in little wound contraction. The less numbers and activity of myofibroblasts found after CO₂ laser surgery compared with scalpel incision were also shown by the study of Zeinoun et al in dorsal tongue mucosa of rats ¹⁰⁾. This study clearly illustrated the result from immunohistochemical staining of vitamin and alpha-smooth muscle actin represented expression of myofibroblasts revealed that the maximum level of myofibroblasts in scalpel excision was almost 3 times higher than CO₂ laser.

There were some studies regarding the appliances for correcting oral soft tissue defects. According to the study of Arikan and Turker ¹¹⁾ reported that the use of stent could prevent muscle re-attachment after free gingival graft for correcting shallow vestibule. Therefore, the CLP patients undertaken surgical vestibular extension were also needed vestibular stents. The stents were required for shaping surgical areas after periodontal surgery and preventing relapse ¹¹⁻¹²⁾.

Regarding the orthodontic appliance, we proposed a design of buccal shield to maintain and guide soft tissue to be healed in the accurate shape as performed after laser surgery and improve soft tissue function allow healing with less tension and tethering scar. The stent consisted of molar tubes to support two buccal arms of the upper labial stent that places at the surgical labial vestibular site to mould the surgical area as surgeon's plan.

Case Report

A fourteen-years-old male patient was presented in the Orthodontic Clinic, Faculty of Dentistry, Khon Kaen University, Khon Kaen, Thailand for assessment of his malocclusion during a long term of treatment since 2 days after birth at Orthodontic Clinic, Faculty of Dentistry, Khon Kaen University. He came with his complaint of anterior crossbite. He had a history of a

non-syndromic bilateral complete cleft lip and palate. The data collection began at the first visit and the treatment began with pre-surgical orthopaedic treatment by using obturator with strapping. Cheiloplasty had been done at 6 months of age and palate repair had been carried out 2 times when the patient age was 9 months and 2 years and 6 months for revision of anterior palate. Lip and palate repair were performed by plastic surgeon at Srinagarind hospital, Faculty of Medicine, Khon Kaen University. Alveolar bone grafting was undertaken when the patient was 9 years old by oral and maxillofacial surgeon at Faculty of Dentistry, Khon Kaen University.

Extraoral examination revealed slightly hyper divergent facial profile with maxillary retrusion. He displayed a bilateral repaired cleft lip with tight upper lip from surgical healing and asymmetry of nose. Upper lip is retrusion while lower lip is protrusion. (**Fig. 1**) Only lower teeth was seen when patient smiled. Intraoral examination showed dental class I on both sides and anterior crossbite with an overjet of -7 mm. Post-surgical soft tissue scarring, labial frenum and excess soft tissue attached at gingival margins of both permanent maxillary central incisors and surrounding areas which restricted tooth movement and trended to limit normal maxillary growth. (**Fig. 2**)

With the consultation and collaboration between the orthodontist (WT) and the oral surgeon (SS), the frenectomy and vestibular extension using 10,600 nm CO₂ laser at 4 W and continuous mode was performed to excise the high attachment of upper labial frenum and to create the depth of the upper anterior buccal vestibule. Then the sculpture technique was undertaken to vaporize the excess soft tissue at the upper lip. The immediate post-operative wound was shown in **Fig. 3**. The lasered wound made possible customized orthodontic appliance of vestibular stent to be placed immediately after surgery (**Fig. 4**). One month after wearing the customized vestibular stent, it was found deeper buccal vestibule of the upper anterior teeth with some soft tissue re-attached at the treated site. (**Fig. 5**) According to this result, the modified design of vestibular stent was used with smoother and thickener vestibular flange and providing passive contact to the treated areas as surgeon planned. (**Fig. 6**) Then, the second laser surgery had done with the same parameter followed by the new buccal shield design appliance which fitted passively to surgical site. There was also an intention to narrow the width of buccal shield for partial coverage of the upper teeth. (**Fig. 7**) This allowed more chance for self-irrigation cleaning with 0.9% normal saline solution beneath the buccal shield

together with using 0.12% chlorhexidine mouth rinse two times a day. In three months of wearing the orthodontic appliance after surgery, the soft tissue remained in the proper form with some inflammation. (**Fig. 8**) Then the corrective orthodontic treatment was continued. One year later after removal of the customized buccal shield, there were normal gingivae. The reconstructed vestibule was covered by normal mucosa with the depth and contour of the tissue as designed. (**Fig. 9**)

Discussion

From the benefits of laser surgery especially CO₂ laser, it was a good choice for surgical procedure in correcting soft tissue defect for surgical treated cleft patients with high labial frenum attachment with excess soft tissue of the upper lip and surgical scars attaching to gingivae resulting shallowing vestibule. In this case with such a multi-area of soft tissue needed correction at the same time, the laser surgeon was unrestricted to design excisional areas and contour the soft tissue by using laser with no need for suture and less scar contracture. We proposed "soft tissue molding technique"; using CO₂ laser surgery releasing high vestibule, frenal and scar tissue attachment combined with orthodontic appliance as a vestibular stent to maintain and guide the healing of soft tissue morphology after surgery. Based on other studies, there are many reasons for choosing CO₂ laser rather than conventional surgery with scalpel and also electro-surgery because it's unique character of bloodless surgery which made clear field and less time consuming on operation, less post-surgical pain and discomfort, no suture required, sterilization of wound and low risk of postoperative infection^{3, 5}). Furthermore, the orthodontic appliance could be apply immediately after the laser surgical procedure due to lesser edema and inflammation besides good hemostasis. There were also no retraction of the tissue than other techniques⁷). It was also shown clearly in our patient that he did not hesitate to undertaken the second laser surgery.

The buccal shield which used as an orthodontic appliance for maintaining vestibular depth against the contracting of tethering scar tissue formation had to design from pre-surgical working model by sectioning of the planned vestibular extended area to prepare for the stent to raise the vestibular contour. The customized vestibular stent for the first operation in this case showed thinner labial flange and poor fitting. Therefore, these may allow some reattachment of tissue. The modified design of buccal shield for the sec-

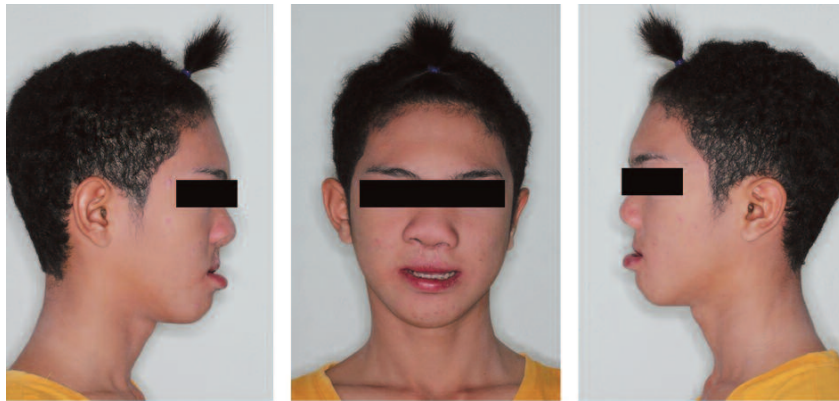


Fig. 1: Facial profile of patient showed surgical repaired cleft lip with anteroposterior maxillary deficiency

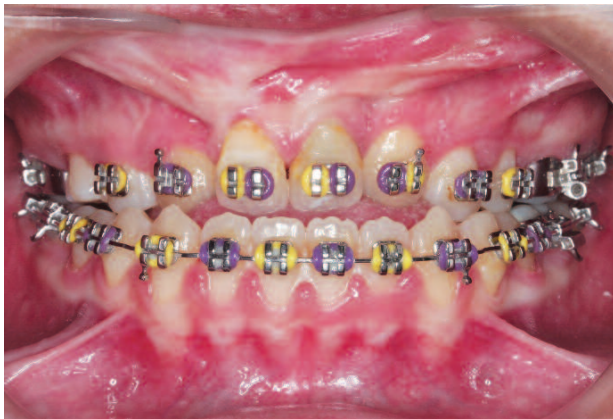

Fig. 2: Soft tissue scarring and labial frenum attachment at gingival margin of the upper teeth resulting shallow vestibule and excess soft tissue of the upper lip

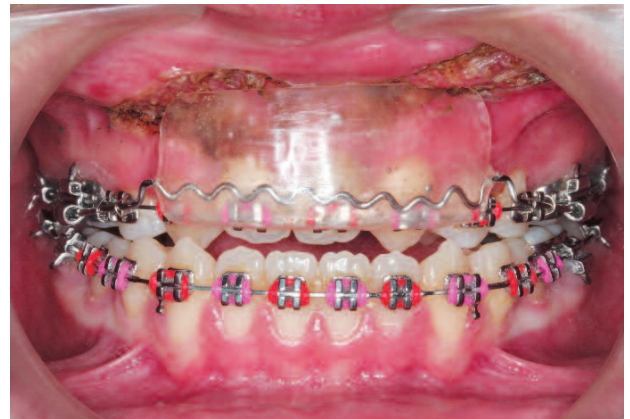

Fig. 4: The customized buccal shield was immediately placed at surgical site.

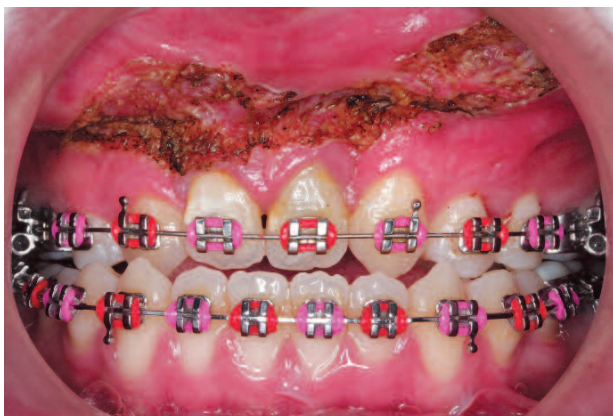


Fig. 3: Immediate post- CO2 laser surgery for soft tissue correction

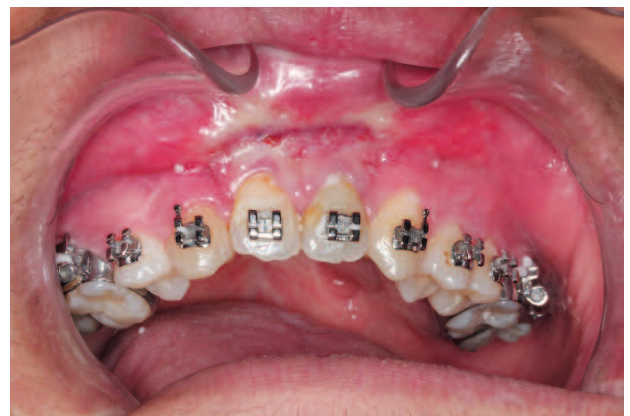

Fig. 5: The customized buccal shield was worn for a month. Some re-attachment and inflammation of soft tissue was found.

ond episode, the flange was more extended superiorly and less involved to coverage the teeth. This enabled us to easier adjust the appliance to be passive fitting on the soft tissue of gingivae and vestibule which provided favorable clinical outcome and patient's satisfactory.

Regarding a further operation in such as a case, Le Fort 1 osteotomy needs to be subsequently undertaken. One of high risk groups for relapsing after the Le Fort 1 advancement of the maxillary was a bilateral cleft lip.¹³⁾ The tethering scar from previous operation may play an part of this disappointing outcome. From

the result of this laser soft tissue molding technique, the reconstructed vestibule was also covered by the normal mucosa with less tension from tethering scar. The quality of tissue in this case may enhance function and esthetic outcome of the Le Fort 1 osteotomy which is a further operation of this patient.

Conclusion

Soft tissue defects of high and large frenum attachment, tethering scar tissue and excess soft tissue after healing of alveolar bone grafting as usual in the CLP

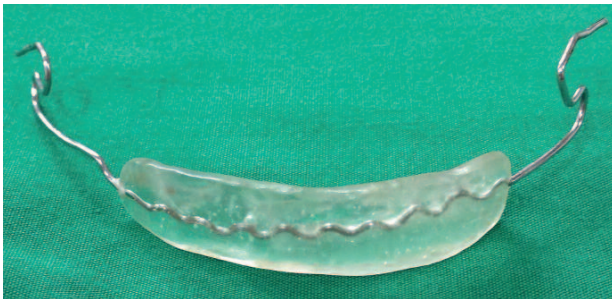

Fig. 6: The new design of buccal shield for soft tissue molding.

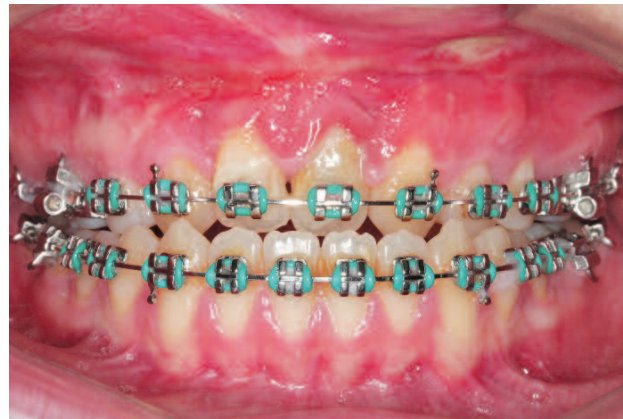


Fig. 8: A 3-month after wearing the customized buccal shield of the second operation, the immediate picture after removal of the appliance showed remaining depth of vestibule with mild inflamed gingivae of the upper anterior teeth.

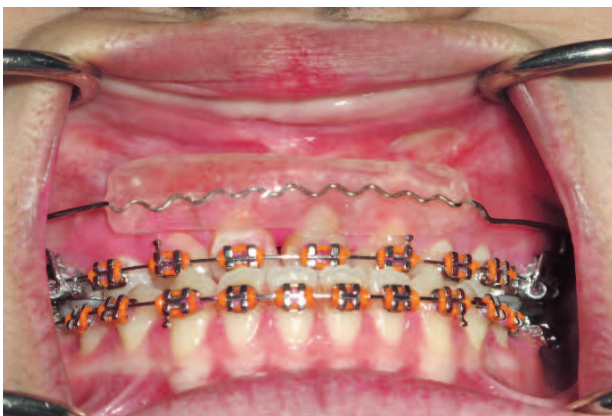


Fig. 7: The new design of the customized buccal shield was placed in the passive contact in the second operation. This photograph was record on a week post-laser surgery. The protein coagulum was observed.

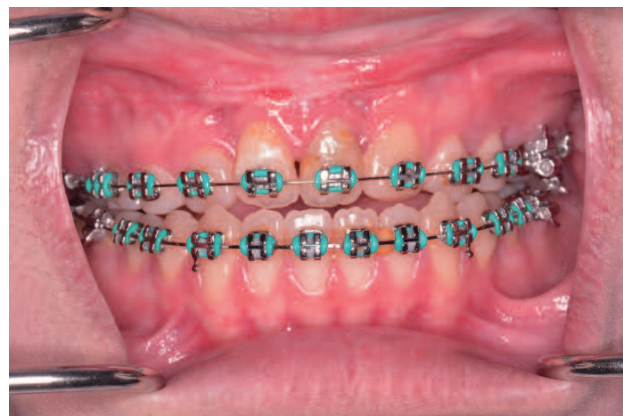


Fig. 9: A year after removal of the customized buccal shield, the gingivae of the upper anterior teeth and the mucosa of the upper anterior buccal vestibule were with in normal limit. The vestibule also was remained in the same depth as an immediate removal of the buccal shield.

patients could be treated by CO₂ laser surgery in combination with customized orthodontic appliance with buccal shield passively contact to surgical site. This

enabled soft tissue molding while healing process and provided appropriate soft tissue morphology without relapsing after not wearing the appliance in a year.

Reference

- 1: Chowchuen B, Godfrey K. Development of a network system for the care of patients with cleft lip and palate in Thailand. *Scandinavian journal of plastic and reconstructive surgery and hand surgery / Nordisk plastikkirurgisk forening [and] Nordisk klubb for handkirurgi*. 2003;37(6):325-31.
- 2: Borba AM, Borges AH, da Silva CSV, Brozoski MA, Naclério-Homem MdG, Miloro M. Predictors of complication for alveolar cleft bone graft. *British Journal of Oral and Maxillofacial Surgery*. 2014;52(2):174-8.
- 3: Akpinar A, Toker H, Lektemur Alpan A, Calisir M. Postoperative Discomfort After Nd: YAG laser and conventional frenectomy: comparison of both genders. *Australian dental journal*. 2015.
- 4: Junior RM, Gueiros LA, Silva IH, de Albuquerque Carvalho A, Leao JC. Labial frenectomy with Nd:YAG laser and conventional surgery: a comparative study. *Lasers in medical science*. 2015;30(2):851-6.
- 5: Haytac MC, Ozcelik O. Evaluation of patient perceptions after frenectomy operations: a comparison of carbon dioxide laser and scalpel techniques. *Journal of periodontology*. 2006;77(11):1815-9.
- 6: Pogrel MA. The carbon dioxide laser in soft tissue preprosthetic surgery. *The Journal of prosthetic dentistry*. 1989;61(2):203-8.
- 7: Tuner J, Hode L. *The New Laser Therapy Handbook*. Grangesberg: Prima Books AB; 2010.
- 8: Fisher SE, Frame JW. The effects of the carbon dioxide surgical laser on oral tissues. *The British journal of oral & maxillofacial surgery*. 1984;22(6):414-25.
- 9: Fisher SE, Frame JW, Browne RM, Tranter RM. A comparative histological study of wound healing following CO₂ laser and conventional surgical excision of canine buccal mucosa. *Archives of oral biology*. 1983;28(4):287-91.
- 10: Zeinoun T, Nammour S, Dourov N, Aftimos G, Luomanen M. Myofibroblasts in healing laser excision wounds. *Lasers in surgery and medicine*. 2001;28(1):74-9.
- 11: Arikan A, Turker SB. The use of a stent-resin-bonded splint combination to stabilize a free gingival autograft. *The Journal of prosthetic dentistry*. 1999;81(2):215-7.
- 12: Frizzera F, Pigossi SC, Tonetto MR, Kabbach W, Marcantonio E, Jr. Predictable interproximal tissue removal with a surgical stent. *The Journal of prosthetic dentistry*. 2014;112(4):727-30.
- 13: Hirano A, Suzuki S. Factors related to relapse after Le Fort I maxillary advancement osteotomy in patients with cleft lip and palate. *The cleft palate-craniofacial journal*. 2001;38(1):1-10.

[Acknowledgements]

We would like to acknowledge Professor Keith Godfrey, a visiting professor in Orthodontics, Khon Kaen University, during 1990 to 2001 for his kind and keen ideas inspiring laser therapy in combination with orthodontic treatment.